

# Challenges in Regenerative Endodontics: A Case Series

Joseph A. Petrino, DDS,\* Kendra K. Boda, DDS, MS,<sup>†</sup> Sandra Shambarger, DDS,\*  
Walter R. Bowles, DDS, MS, PhD,\* and Scott B. McClanahan, DDS, MS\*

## Abstract

**Introduction:** An immature tooth with pulpal necrosis and apical periodontitis presents a unique challenge to the endodontist. Endodontic treatment options consist of apexification, apical barriers, or more recently, revascularization. The purpose of this case series is to report three cases that used revascularization protocol as described by Banchs and Trope. Each case presented its own special circumstances and challenges. The lessons learned from each case provided guidance for more predictable outcomes on subsequent cases.

**Methods:** Six immature teeth with apical periodontitis (in three patients) were treated via the revascularization protocol using irrigants, a triple antibiotic paste, and a coronal seal of mineral trioxide aggregate and composite. **Results:** For follow-up, all six teeth showed resolution of periapical radiolucencies, whereas three of six teeth showed continued root development. Two teeth displayed a positive response to vitality testing.

**Conclusions:** Results from this case series show that revascularization is a technically challenging but effective treatment modality for the immature tooth with apical periodontitis. Based on this case series, the following recommendations are made to help with the revascularization technique: (1) clinicians should consider the use of an anesthetic without a vasoconstrictor when trying to induce bleeding, (2) a collagen matrix is useful for the controlled placement of MTA to a desired and optimal level, (3) patients/parents should be informed about the potential for staining, especially in anterior teeth when the paste contains minocycline, and (4) patient/parent compliance with the necessary multiple appointment treatment plan may be significant for case selection. (*J Endod* 2010;36:536–541)

## Key Words

CollaPlug, mepivacaine, mineral trioxide aggregate, regeneration, revascularization

The treatment of pulpal necrosis in an immature tooth with an open apex presents a unique challenge to the dentist. Before 2004, clinicians relied on traditional apexification procedures or the use of apical barriers to treat immature teeth with pulpal necrosis. Traditional apexification uses long-term calcium hydroxide dressings to promote the formation of a calcified barrier that an obturation material can be placed against. Apexification has proven to be highly predictable (1, 2) but has the downside of multiple appointments over a period of months plus an increased susceptibility to cervical fracture (3, 4).

The artificial apical barrier technique uses a barrier material that is placed at the apex to facilitate obturation procedures by containing the obturation material within the canal. The material of choice for this procedure is ProRoot Mineral Trioxide Aggregate (MTA) (Dentsply Tulsa Dental, Tulsa, OK) (5, 6). The technique is predictable and successful (7, 8) and reduces the number of treatment appointments (9). The disadvantage of both traditional apexification and artificial apical barriers is that neither allows for thickening of the root wall or continued development of the root.

One of the first revascularization research efforts was a case report in which the immature tooth was treated with irrigation and disinfection using two antimicrobial agents (metronidazole and ciprofloxacin) with successful revascularization (10). In 2004, Banchs and Trope (11) published a case report describing a new treatment procedure for the management of the open apex called “revascularization.” The protocol differs from other apexification techniques in that disinfection of the canal is performed with both sodium hypochlorite (NaOCl) and chlorhexidine (CHX) and, as Hoshino et al (12) described, using a combination of three antibiotics (ciprofloxacin, metronidazole, and minocycline). At a subsequent appointment, the paste is removed and bleeding is induced into the canal. The canal is sealed with MTA, and, after the MTA has set, a bonded restoration is placed. Unlike traditional apexification or the use of apical barriers, revascularization procedures allow for an increase in both root wall thickness and the length of the root. Additionally, the treatment time can be completed in fewer visits than traditional apexification. Further research has compared this method with placement of Ca(OH)<sub>2</sub> or formocresol (13). Increased root lengths were seen in the triple antibiotic and Ca(OH)<sub>2</sub> groups, whereas only the triple antibiotic group showed increased root wall thickness. Although successful in some cases, there are still areas of concern. Some problems we discovered are presented in this case series using a revascularization protocol. Each case presented its own special circumstances and challenges, and the lessons learned from each case helped improve the treatment of subsequent cases.

## Case 1

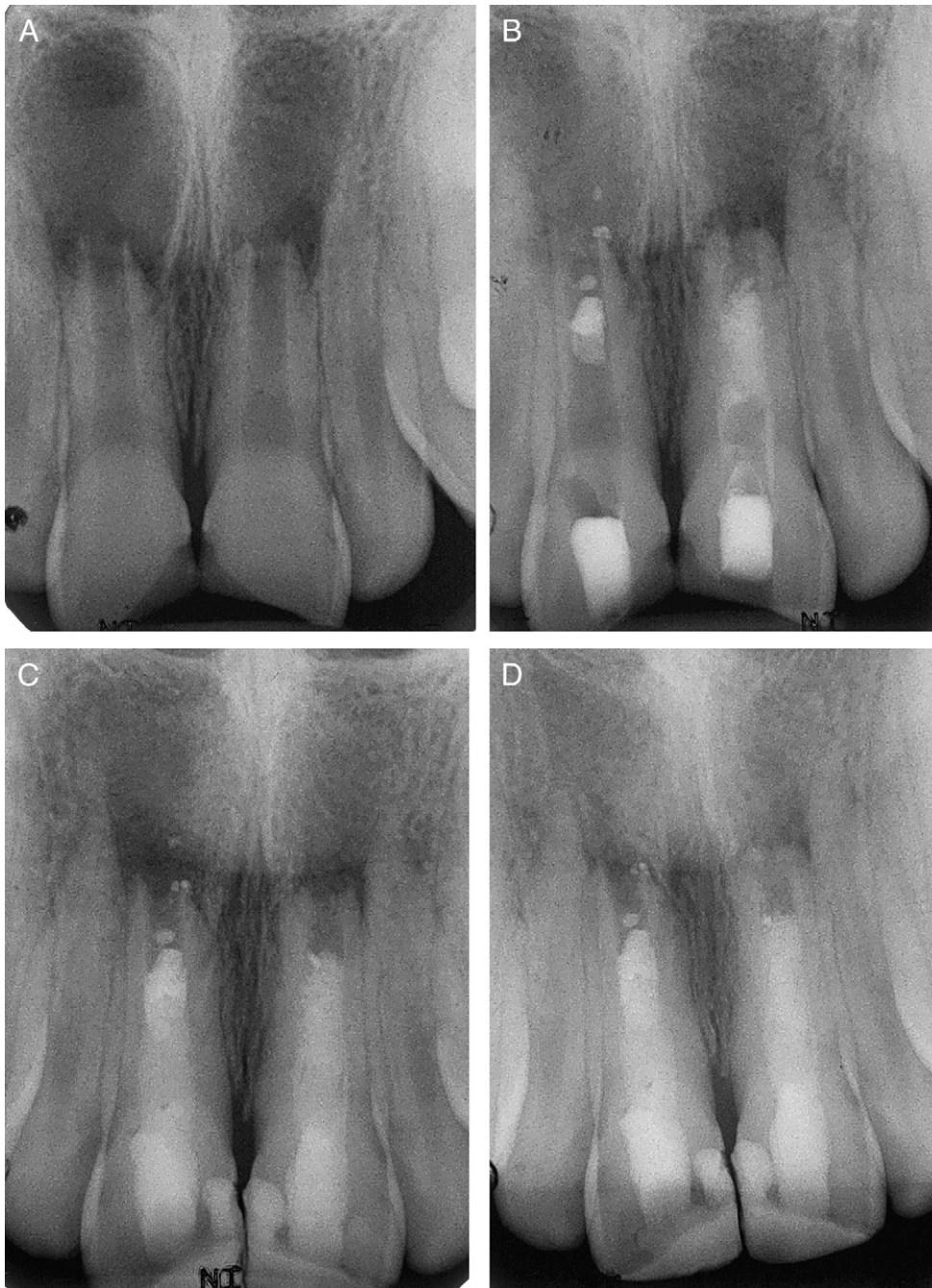A healthy 13-year-old male was referred for evaluation and treatment of teeth numbers 8 and 9. The patient reported that he had broken his front teeth subsequent to a fall nearly 6 years prior. A sinus tract was noted on the buccal mucosa above tooth number 9. After clinical and radiographic examination (Fig. 1A), the diagnosis was as follows: tooth number 8 - pulpal necrosis, asymptomatic apical periodontitis and tooth number 9 - pulpal necrosis and chronic apical abscess. Revascularization procedures were recommended for both teeth.

After informed consent was obtained, the teeth were anesthetized with 2% lidocaine with 1:100,000 epinephrine, isolated with a rubber dam, and accessed. Upon access, hemorrhagic, purulent exudate was found in both teeth. The canals were irrigated with 20 mL of 5.25% NaOCl, followed by 20 mL of saline, and then 10 mL of 0.12%

From the \*Division of Endodontics, University of Minnesota School of Dentistry, Minneapolis, MN; and <sup>†</sup>Private Practice, Eagan, MN.

Address requests for reprints to Dr Walter Bowles, Division of Endodontics, University of Minnesota School of Dentistry, 8-166 Moos Tower, 515 Delaware St SE, Minneapolis, MN 55455. E-mail address: bowle001@umn.edu. 0099-2399/\$0 - see front matter

Copyright © 2010 American Association of Endodontists. doi:10.1016/j.joen.2009.10.006



**Figure 1.** (Case 1) This case highlights the difficulty with induction of bleeding when local anesthetic with vasoconstrictor is used and shows problems with initial placement of MTA. A 13-year-old male presented with fractured incisal edges on teeth 8 and 9. (A) Radiograph showed incompletely formed apices on teeth 8 and 9, and periapical lesion approximately  $1 \times 1$  cm associated with both teeth. (B) Placement of MTA barrier in teeth 8 and 9 after induction of bleeding. The problem inducing bleeding was overcome by using an anesthetic that did not contain a vasoconstrictor. Barrier placement was farther apical than desired. (C) Completion of composite restorations. Lesions on both teeth at this time appear to be showing signs of healing. (D) A 1-year follow-up showed increased thickness of the apical area on tooth number 9; no apparent changes observed on tooth number 8 and continued healing of lesions. Both teeth 8 and 9 lacked a response to vitality testing at this follow up examination.

CHX. This became the irrigation protocol for all four cases. The saline rinse was used to prevent the interaction between NaOCl and CHX (14). The canals were dried, and a triple antibiotic paste consisting of ciprofloxacin, metronidazole, and minocycline (100 mg of each drug in a 0.5-mL total volume) was placed. The compounding of the antibiotic paste was standardized for all four cases. The teeth were then temporized.

The patient returned to the clinic 3 weeks later. The patient remained asymptomatic, and the sinus tract was no longer present. The teeth were again anesthetized with 2% lidocaine with 1:100,000 epinephrine, isolated with a rubber dam, and accessed. The triple antibiotic paste was removed using 10 mL of 5.25% NaOCl per tooth, and the canals were dried. Using an endodontic explorer and hand file, all attempts to induce bleeding into the canal space on each tooth were

unsuccessful. Because of time limitations of the schedule that day, the canals were irrigated with 5 mL of 5.25% NaOCl and dried with paper points and the teeth were temporized using intermediate restorative material restorations.

The patient returned to the clinic 1 week later. The teeth were anesthetized at this appointment using 3% mepivacaine without a vasoconstrictor rather than the anesthetic used at the first appointment. The teeth were isolated using a rubber dam and accessed. The canals were irrigated using 10 mL of 5.25% NaOCl and dried. The apical tissue in tooth number 9 was irritated using an 80 K-file, and a blood clot was formed 4 mm apical to the cemento-enamel junction (CEJ) on tooth number 9. After 15 minutes, white MTA (Dentsply Tulsa Dental, Tulsa, OK) was placed over the blood clot. The placement of MTA resulted in movement of the MTA further apically than desired. It was decided to leave the MTA and continue with barrier placement. A wet cotton pellet was placed against the MTA in tooth number 9. Bleeding into the canal on tooth number 8 was induced, but the establishment of a blood clot at the desired level of 1 to 2 mm below the CEJ was not obtained because bleeding only went into the apical 3 mm of the tooth. Induction of bleeding was insufficient to allow for formation of a blood clot to the desired level with a suitable matrix for the placement of MTA. Tooth number 8 was irrigated with 5 mL of 5.25% NaOCl and dried with paper points. Both teeth were temporized.

The patient returned approximately 2 months later. The patient was asymptomatic. The teeth were again anesthetized using 3% mepivacaine without a vasoconstrictor. Tooth number 8 was isolated with a rubber dam and accessed. The canal was irrigated with 10 mL of 5.25% NaOCl. The apical tissue of tooth number 8 was irritated with an 80 K-file, and a blood clot was established 4 mm below the CEJ. After 15 minutes, white MTA was placed over the blood clot, with MTA placement much farther apically than desired. A wet cotton pellet was placed over the MTA, and the tooth was temporized (Fig. 1B).

The patient returned asymptomatic 18 days later. At this appointment, no anesthetic was used. Teeth 8 and 9 were isolated using a rubber dam, and the canal on each tooth was accessed to the level of the MTA. The canals were irrigated with 5 mL of 5.25% NaOCl, and the set of the MTA was verified. The teeth were then restored using composite (Fig. 1C).

At the 1-year follow-up, the patient was asymptomatic. Clinical examination showed no signs of edema, erythema, or sinus tracts. Teeth 8 and 9 were nonsensitive to percussion and palpation, and all probing depths were within normal limits. Radiographic examination showed healing of the radiolucent lesions on both teeth (Fig. 1D). Tooth number 9 showed increased thickness of the apical area. No increase in the thickness of the root walls or increase in the length of the root was observed on tooth number 8. The patient lacked a response to vitality testing at this visit.

### Case 2

An 11-year-old male was referred from the Pediatric Dental Clinic to manage a carious exposure on tooth number 29. The patient also reported a past history of a toothache on the lower left side, which was currently asymptomatic. Additionally, a sinus tract was noted on the buccal mucosa adjacent to tooth number 20. After clinical and radiographic examination, the diagnoses were as follows: tooth number 29 - pulpal necrosis and asymptomatic apical periodontitis and tooth number 20 - pulpal necrosis and chronic apical abscess (Fig. 2A and B). The revascularization protocol was recommended, and informed consent was obtained.

Each tooth was anesthetized with 3% mepivacaine without a vasoconstrictor, isolated with a rubber dam, and accessed and irrigated with

the same irrigation sequence as in case 1. The teeth were dried, triple antibiotic paste was placed, and the teeth were temporized.

The patient returned asymptomatic 34 days later. The sinus tract on tooth number 20 had resolved. After local anesthesia with 3% mepivacaine without a vasoconstrictor was achieved, the teeth were isolated with a rubber dam, accessed, and irrigated with 5.25% NaOCl, and the canals were dried. The apical tissues were irritated with files to induce bleeding. A blood clot was achieved approximately 3 mm below the CEJ. CollaPlug (Zimmer Dental, Carlsbad, CA) fibers were placed on the blood clot, and then a 3-mm white MTA barrier was placed. A moist cotton pellet was placed over the MTA, and the teeth were temporized. The patient returned 1 week later for the placement of a composite restoration (Fig. 2C and D).

The patient returned to the clinic for the 1-year follow-up examination and was asymptomatic. No signs of edema, erythema, or sinus tracts were noted. Neither teeth 20 nor 29 were sensitive to percussion or palpation. Radiographic examination showed healing of lesions associated with each tooth. In addition, increased thickening of the root walls and the root length was observed on both teeth (Fig. 2E and F). During this visit, the patient had a positive response to vitality testing on both teeth.

### Case 3

A healthy 6-year-old female was referred from the Pediatric Dental Clinic. The patient had teeth D, 8, 9, and G avulsed approximately 6 months previously, with replantation of teeth 8 and 9. After clinical and radiographic examination (Fig. 3A), the diagnosis for both teeth 8 and 9 was pulpal necrosis and asymptomatic apical periodontitis. The revascularization protocol was recommended.

Three weeks after evaluation, the patient presented for initiation of the treatment, and informed consent was obtained. The patient was sedated using nitrous oxide to aid in patient management. The teeth were anesthetized with 3% mepivacaine without a vasoconstrictor, isolated with a rubber dam, and accessed. Upon access, hemorrhagic exudate was noted in both teeth. The canal in each tooth was irrigated in a similar fashion to the previous cases. The triple antibiotic paste was placed, and the teeth were temporized.

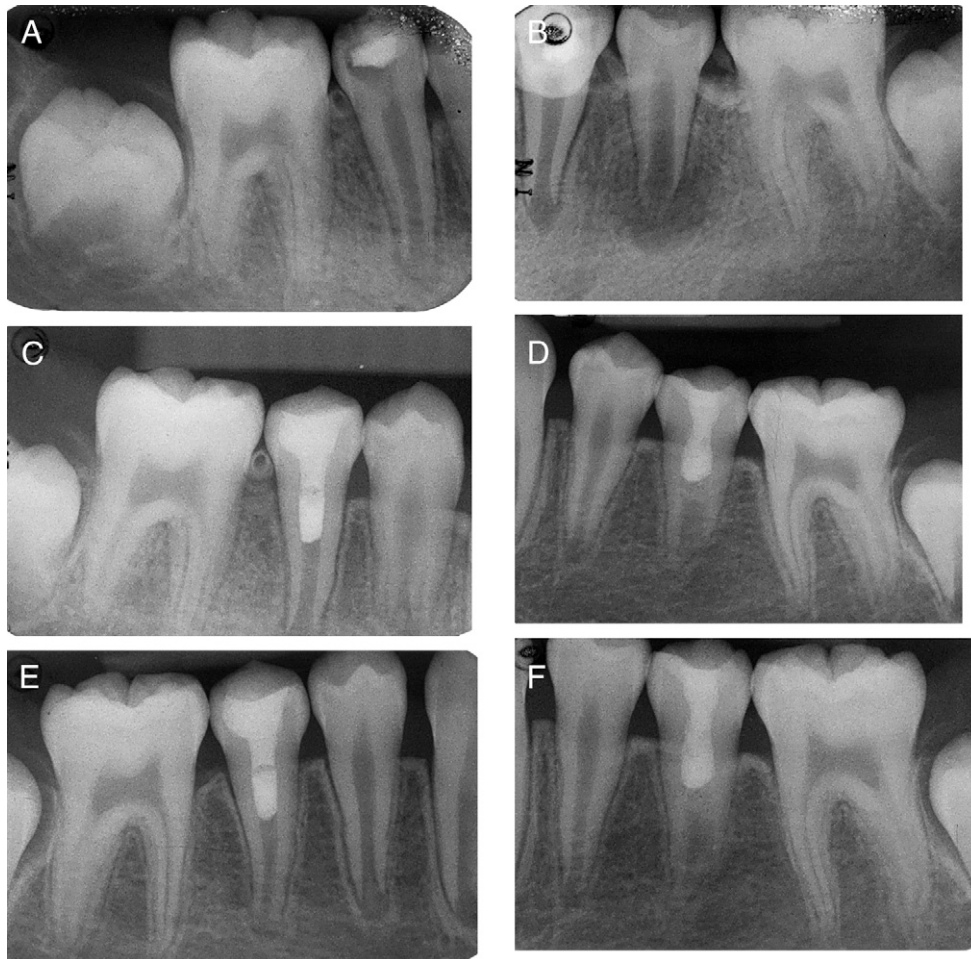
Two weeks later, the patient returned asymptomatic for the continuation of treatment. She was again sedated using nitrous oxide. The teeth were anesthetized with 3% mepivacaine without a vasoconstrictor, isolated with a rubber dam, and accessed. The canal in each tooth was irrigated using 10 mL of 5.25% NaOCl and then dried. The apical tissues of teeth 8 and 9 were irritated using K-files to induce bleeding. A layer of CollaPlug was placed on top of the blood clot as a matrix for the condensation of MTA. Once wicking of blood into the CollaPlug matrix was noted, white MTA was placed. A moist cotton pellet was placed over the MTA, and the teeth were temporized (Fig. 3B).

Ten days later, the patient returned to the clinic for placement of definitive composite restorations. The patient had remained asymptomatic, but as compared with tooth number 9, discoloration of tooth number 8 was noted (Fig. 3C).

At the 6-month follow up examination, the patient remained asymptomatic. All teeth in the maxillary anterior sextant were nonsensitive to percussion and palpation. All probing depths were within normal limits. Radiographic examination showed an increase in root wall thickness and length in both teeth 8 and 9 (Fig. 3D). Tooth number 8 showed formation of an apical barrier. Both teeth showed healing of apical radiolucent lesions. Neither tooth displayed a response to vitality testing.

### Discussion

This report describes six teeth in three patients that underwent the revascularization protocol as described by Banchs and Trope (11). The

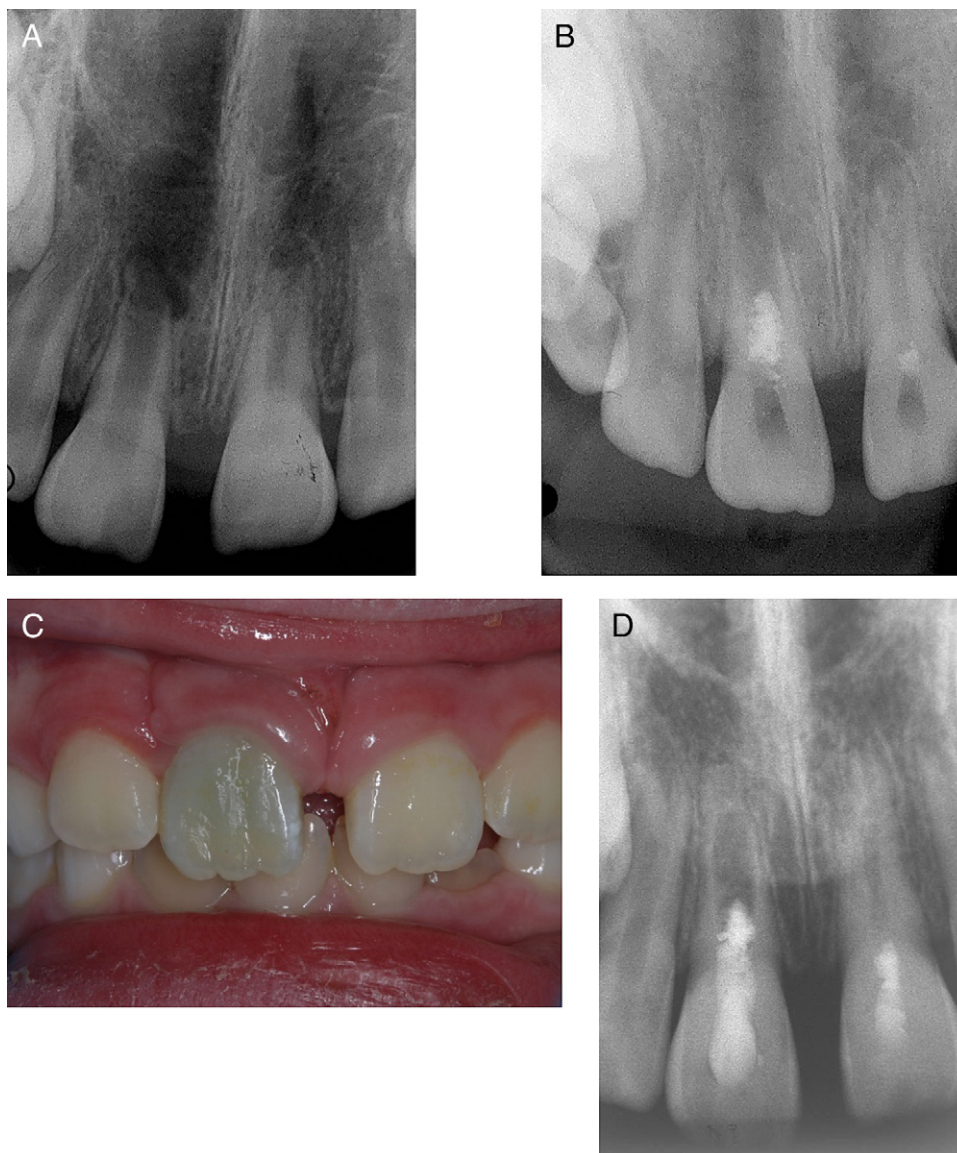


**Figure 2.** (Case 2) This case shows how the use of a local anesthetic without a vasoconstrictor and the use of a collagen matrix allowed for more predictable induction of bleeding and optimal placement of MTA. An 11-year-old male presented to clinic for management of a carious exposure on tooth number 29. The patient also reported a history of discomfort on tooth number 20. (A) A radiograph showing carious exposure of pulp and a well-demarcated radiolucent lesion on tooth number 29. (B) A radiograph showing incomplete development of tooth number 20 and a well-demarcated radiolucency. (C and D) Radiographs showing placement of MTA and completion of composite restoration on tooth 29 (C) and 20 (D). In both teeth, CollaPlug was used as a matrix to aid placement of MTA. (D) A radiograph showing placement of MTA and completion of composite restoration on tooth 20. In this case, CollaPlug was used as a matrix to aid placement of MTA. (E and F) A 1-year follow-up radiograph showing healing of the radiolucent lesion and increased thickness of the root wall and length on tooth 29 (E) and 20 (F). Both teeth had a positive response to vitality testing at this follow-up examination. The formation of an apical barrier is also seen with tooth 20 (F).

decision to use revascularization instead of apexification was made primarily because of the potential for increased root length and thickness of root walls. Because this protocol is very technically demanding, elements of the technique evolved from case to case. Changes may occur with this technique as more research is completed. Recent studies have shown that irrigation with CHX may be detrimental to stem cells (15) and may require a modification of our irrigation method with this technique.

In case 1, several challenges in the management were overcome and applied to the next case. First, it took several attempts to induce bleeding into the canal space. We found that inducing bleeding was easier when an anesthetic solution did not contain a vasoconstrictor. Both animal and human studies have shown that there is a significant reduction in pulpal blood flow after infiltration injection of anesthetics containing epinephrine (16–18). We cannot rule out any effect the triple antibiotic paste may have had on bleeding reduction, but because the removal of epinephrine from our anesthetic allowed the induction of bleeding, we recommend this technique. Research has shown that the “inclusion of a blood clot in the canal space tended to improve the

revascularization outcome” (19), and the induction of bleeding into the canal may provide stem cells, which can induce dentin formation. Others show regeneration with or without formation of a blood clot (20), suggesting that additional research is needed in this area. Second, the placement of MTA over a blood clot was technically difficult, and condensation resulted in apical displacement of the material, which looked as though an apical barrier had been placed. This may have been the cause of the subclinical results for this case. This is also shown for the placement of  $\text{Ca}(\text{OH})_2$ , where better results were seen when the placement of the  $\text{Ca}(\text{OH})_2$  was restricted to the coronal half of the tooth (13). The placement of MTA and a blood clot would likely depend on presenting circumstances; the more developed the root, theoretically, the more apical it could be placed. Additionally, depending on where you can establish a blood clot may have an influence on the placement of MTA. Ideally, the coronal edge of MTA should be placed 1 to 2 mm apical to the CEJ to allow for more root development versus 3 to 4 mm as described by Banchs and Trope (11). The use of a 1-mm thick glass ionomer material may allow for more cervical placement. Results from this case also suggest that a resorbable barrier could be placed



**Figure 3.** (Case 3) A 6-year-old female presenting to the clinic 6 months after teeth 8 and 9 were avulsed. Management of this case allowed for more predictable induction of bleeding and optimal placement of MTA using techniques learned from cases 1 through 2 above. This case, however, showed the potential for staining of tooth structure attributed to the minocycline in the antibiotic paste. (A) A radiograph revealed open apices on teeth 8 and 9 and associated periapical lesions. (B) Placement of MTA barrier over CollaPlug matrix. (C) A clinical photograph showing blue staining on tooth 8 attributed to the minocycline in the antibiotic paste. (D) A 9-month follow-up radiograph showing healing of lesions on teeth 8 and 9. Increased root length and root wall thickness noted on tooth 9. Formation of an apical barrier on tooth 8 was noted. Both teeth 8 and 9 lacked a response to vitality testing at this examination.

to serve as a matrix for MTA. The case series from 2007 described the use of CollaTape (Zimmer Dental) as a matrix for the placement of MTA (21). The authors reported that wetting of the matrix via blood was observed through the microscope, and MTA was placed over the matrix. Follow-up radiographs in the 2007 case series showed continued apical development and resolution of the lesion. Cases 2 and 3 used the lessons learned from our first case. CollaPlug was chosen in cases 2 and 3 instead of CollaTape because CollaPlug fibers handle more easily than the tape.

The follow-up times for the cases ranged from 9 months to 1 year. The nature of a school of dentistry patient population for Endodontic and Pediatric Dental Clinics makes compliance with appointment intervals, multiple appointments, and follow-ups a significant challenge. Because revascularization cases require stringent follow-up, noncompliance of the patient/guardian may be a contraindication for these

procedures. In the six teeth included here, resolution of the apical radiolucencies is seen. Additionally, of these teeth, three showed continued apical development, two showed possible formation of an apical barrier, and one showed no apparent change apically. Two of the six teeth had a positive response to vitality testing. It is important to note that the elimination of vasoconstrictor from the local anesthetic and the addition of a collagen matrix allowed for more predictable induction of bleeding and optimal placement of MTA.

The staining noted on tooth number 8 in case 3 can be attributed to the minocycline in the antibiotic paste, which has been noted from our studies on extracted teeth (unpublished data) and may have been caused by residual paste in the pulp chamber or neck of the tooth. Another source of staining may be residual tissue above the MTA or even the MTA material. The restorative and esthetic management can be challenging. The potential for staining does not occur every time

with minocycline in the paste; this was not seen in the adjacent tooth. Staining prevention may require the elimination of minocycline in the paste for the treatment of anterior teeth or sealing dentinal tubules within the chamber (22).

Research has shown that the triple antibiotic paste is effective in disinfecting the canal (23). The compounding of the triple antibiotic paste was standardized in this series of cases. Each batch of the triple antibiotic paste was compounded within 24 hours of use and was removed from the teeth between 14 and 35 days after placement. For all of the cases in this series, the paste was compounded by the same individual, who trained as a pharmacist before becoming an endodontist. The antibiotic paste contained 100 mg of each of the three antibiotics in a total volume of 0.5 mL. The pharmaceutical carriers propylene glycol and polyethylene glycol were used. Propylene glycol is often used as a solvent, preservative, and humectant in pharmaceutical preparations, with patch tests showing it to be innocuous, whereas polyethylene glycol is used as vehicles in pharmaceutical and cosmetic preparations and are chemically inert (24). These ingredients allow increased solubility and delivery of the paste into the canal. Aqueous solutions of antibiotics can often degrade, and this degradation is heightened by increased temperature and pH.

In conclusion, the revascularization treatment is minimally invasive but technically challenging. Based on the experiences of the three cases, the following “clinical tips” are offered for consideration: (1) clinicians should consider the use of an anesthetic without a vasoconstrictor when trying to induce bleeding; (2) a collagen matrix is useful for the controlled placement of MTA to a desired and optimal level, with only light pressure placed on the MTA during packing; (3) patients and parents should be informed about the potential for staining, especially in anterior teeth when the paste contains minocycline; and (4) patient and parent compliance with the necessary multiple appointment treatment plan may be significant for case selection.

### Acknowledgments

*The authors would like to thank the pediatric dental residents for referring the cases to our department.*

### References

1. Yates JA. Barrier formation time in non-vital teeth with open apices. *Int Endod J* 1988;21:313–9.
2. Ghose IJ, Baghdady VS, Hikmat YM. Apexification of immature apices of pulpless permanent anterior teeth with calcium hydroxide. *J Endod* 1987;13:285–90.

3. Andreasen JO, Farik B, Munksgaard EC. Long-term calcium hydroxide as a root canal dressing may increase risk of root fracture. *Dent Traumatol* 2002;18:134–7.
4. Doyon GE, Dumsha T, von Fraunhofer JA. Fracture resistance of human root dentin exposed to intracanal calcium hydroxide. *J Endod* 2005;3:895–7.
5. Hachmeister DR, Schindler WG, Walker WA 3rd, et al. The sealing ability and retention characteristics of mineral trioxide aggregate in a model of apexification. *J Endod* 2002;28:386–90.
6. Felipe WT, Felipe MC, Rocha MJ. The effect of mineral trioxide aggregate on the apexification and periapical healing of teeth with incomplete root formation. *Int Endod J* 2006;39:2–9.
7. Holden DT, Schwartz SA, Kirkpatrick TC, et al. Clinical outcomes of artificial root-end barriers with mineral trioxide aggregate in teeth with immature apices. *J Endod* 2008;34:812–7.
8. Witherspoon DE, Small JC, Regan JD, et al. Retrospective analysis of open apex teeth obturated with mineral trioxide aggregate. *J Endod* 2008;34:1171–6.
9. Simon S, Rilliard F, Berald A, et al. The use of mineral trioxide aggregate in one-visit apexification treatment: a prospective study. *Int Endod J* 2007;40:186–97.
10. Iways S, Ikawa M, Kubota M. Revascularization of an immature permanent tooth with apical periodontitis and sinus tract. *Dent Traumatol* 2001;17:185–7.
11. Banchs F, Trope M. Revascularization of immature permanent teeth with apical periodontitis: new treatment protocol? *J Endod* 2004;30:196–200.
12. Hoshino E, Kurihara-Ando N, Sato I, et al. In-vitro antibacterial susceptibility of bacteria taken from infected root dentine to a mixture of ciprofloxacin, metronidazole and minocycline. *Int Endod J* 1996;29:125–30.
13. Bose R, Nummikoski P, Hargreaves KM. A retrospective evaluation of radiographic outcomes in immature teeth with necrotic root canal systems treated with regenerative endodontic procedures. *J Endod* 2009 (in press).
14. Basrani BR, Manek S, Sodhi RN, et al. Interaction between sodium hypochlorite and chlorhexidine gluconate. *J Endod* 2007;33:966–9.
15. Trevino EG, Henry MA, Patwardhan A, et al. The effect of different irrigation solutions on the survival of stem cells of the apical papilla (SCAP) in a PRP scaffold in human root tips. *J Endod* 2009;35:428.
16. Ahn J, Pogrel MA. The effects of 2% lidocaine with 1:100,000 epinephrine on pulpal and gingival blood flow. *Oral Surg Oral Med Oral Pathol Oral Radiol Endod* 1998; 85:197–202.
17. Chng HS, Pitt Ford TR, McDonald F. Effects of prilocaine local anaesthetic solutions on pulpal blood flow in maxillary canines. *Endod Dent Traumatol* 1996;12:89–95.
18. Kim S, Edwall L, Trowbridge H, et al. Effects of local anesthetics on pulpal blood flow in dogs. *J Dent Res* 1984;63:650–2.
19. Thibodeau B, Teixeira F, Yamauchi M, et al. Pulp revascularization of immature dog teeth with apical periodontitis. *J Endod* 2007;33:680–9.
20. Jung I, Lee S, Hargreaves KM. Biologically based treatment of immature permanent teeth with pulpal necrosis: a case series. *J Endod* 2008;34:876–87.
21. Jung IY, Lee SJ, Hargreaves KM. Biologically based treatment of immature permanent teeth with pulpal necrosis: a case series. *J Endod* 2008;34:876–87.
22. Reynolds K, Johnson JD, Cohenca N. Pulp revascularization of necrotic bilateral bicuspids using a modified novel technique to eliminate potential coronal discoloration: a case report. *Int Endod J* 2009;42:84–92.
23. Windley W 3rd, Teixeira F, Levin L, et al. Disinfection of immature teeth with a triple antibiotic paste. *J Endod* 2005;31:439–43.
24. Remington: The science and practice of pharmacy. In: Genarro A, ed. 20th ed. Baltimore, MD: Lippincott Williams and Wilkins; 2000.